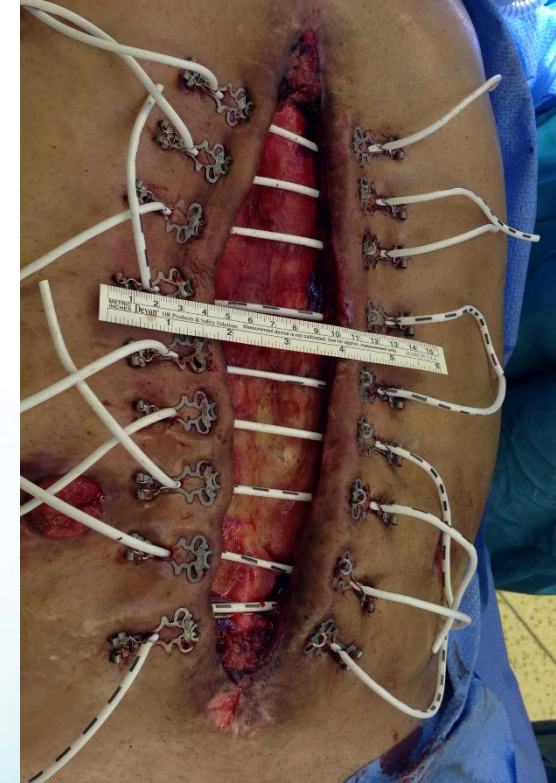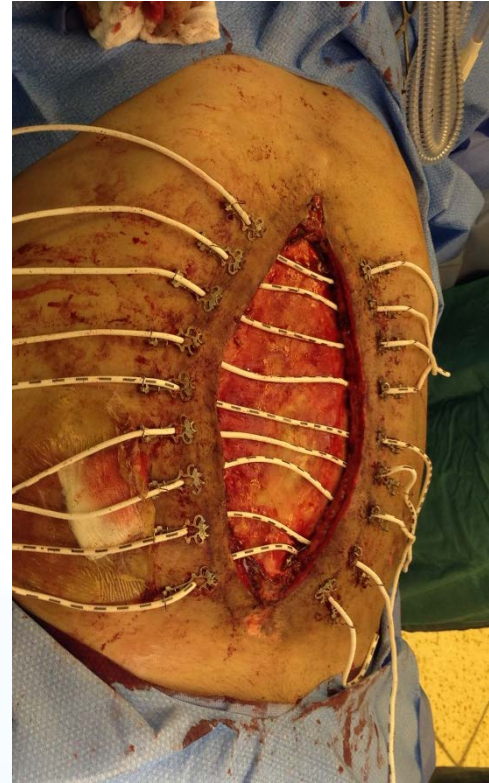

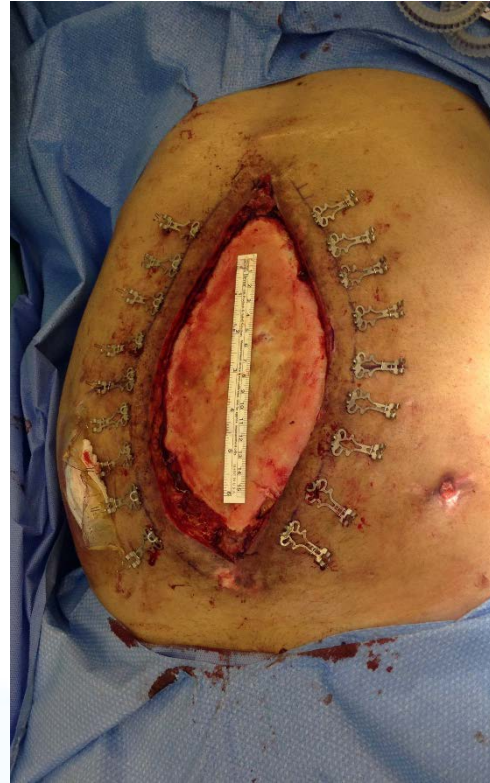
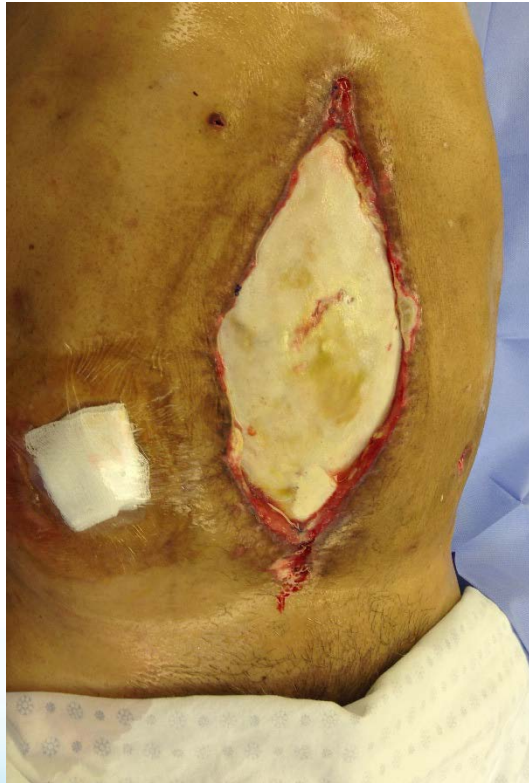ABRA ABDOMINAL CASE STUDY, DECEMBER, 2015

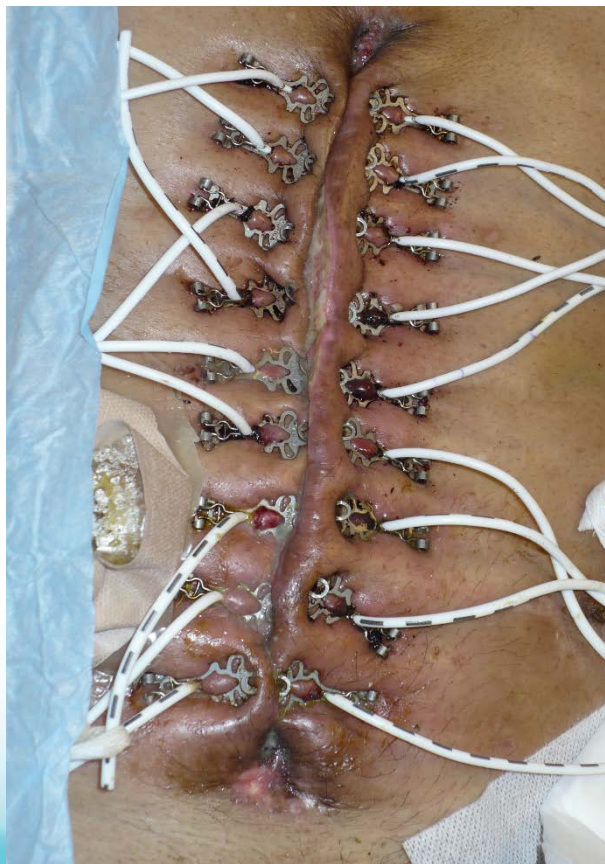
BRITISH COLUMBIA, CANADA

- **This is a 61 yr. old male underwent Colectomy procedure for cancer Sept, 2015.**
- **Post – op - fistula and sepsis.**
- **Nov 6 – Wound repaired with Component Separation and large piece of Biologic mesh.**
- **Nov 30 – skin closure dehisced leaving large skin defect over mesh.**
- **Dec 2 – patient taken to the OR for installation of ABRA Surgical Skin Anchor system. Wound covered with wet/dry dressing.**
- **ABRA elastomers adjusted daily.**
- **Dec 11 – ABRA removed and full skin closure performed.**
- **A couple small gaps developed along the suture line but the closure held.**
- **Jan 6, 2016 – final follow up picture of incision line with minor defects healing by secondary intention.**

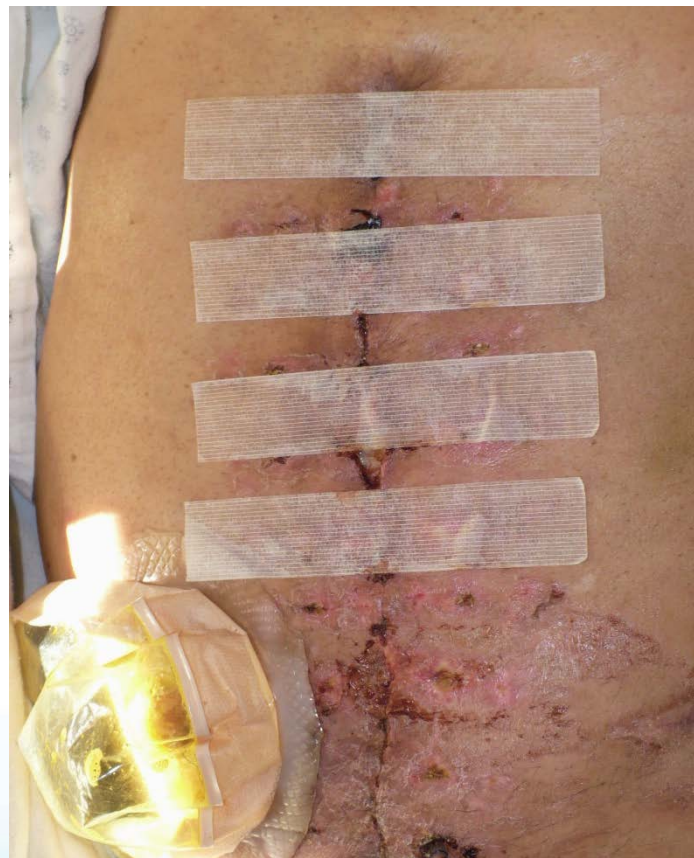ABRA INSTALLATION Day 1



ABRA Day 7



ABRA Closure Day 9



ABRA Follow up Day 35

